

Original Article

Open Access



Olecranon bone grafting for the treatment of nonunion after distal finger replantation

Burak Sercan Ercin^{1,2}, Fatih Kabakas^{1,2}, Musa Kemal Keles^{1,2}, Ismail Bulent Ozcelik^{1,3,4}, Berkan Mersa^{1,3,4}

¹IST-EL Microsurgery Group, Istanbul 34245, Turkey.

²Department of Plastic Surgery and Hand Surgery, Medicalpark Gebze Hospital, Kocaeli 41400, Turkey.

³Department of Hand Surgery, Yeni Yuzyil University, Gaziosmanpasa Hospital, Istanbul 34245, Turkey.

⁴Nisantasi University, Istanbul 34398, Turkey.

Correspondence to: Dr. Burak Sercan Ercin, Department of Plastic Surgery and Hand Surgery, Medicalpark Gebze Hospital, Kocaeli 41400, Turkey. E-mail: bsercin@gmail.com

How to cite this article: Ercin BS, Kabakas F, Keles MK, Ozcelik IB, Mersa B. Olecranon bone grafting for the treatment of nonunion after distal finger replantation. *Plast Aesthet Res* 2020;7:38. <http://dx.doi.org/10.20517/2347-9264.2020.56>

Received: 29 Mar 2020 **First Decision:** 4 Jun 2020 **Revised:** 12 Jun 2020 **Accepted:** 7 Jul 2020 **Published:** 19 Jul 2020

Academic Editor: A Thione **Copy Editor:** Cai-Hong Wang **Production Editor:** Tian Zhang

Abstract

Aim: Although not very popular, the olecranon bone graft is a useful option for this type of operation due to the minimal donor morbidity and its ease of use in small bone defect reconstruction and non-union therapy. To our best knowledge, few studies have evaluated the use of the olecranon bone graft as a treatment for non-union after distal finger replantation. Our aim in this report was to present our experience of using olecranon grafts in our nonunion patients undergoing distal replantations.

Methods: Between 2013 and 2019, a total of 14 patients who developed nonunion or had segmental bone defects due to the injury were included in the study. Retrospectively the results were analyzed in terms of complication and union rates.

Results: The mean follow-up period was 37 months (range 8-72 months). No major complications were seen in the donor region or recipient regions. One patient developed necrosis in the nail bed and one patient had a hematoma in the donor site. The minor complications were solved without any problem.

Conclusion: In conclusion, we found the olecranon bone grafting for the treatment of nonunion after distal finger replantation is a safe and convenient method. It can be preferred as the first choice for nonunions of distal finger replantations.

Keywords: Bone, olecranon, graft, replantation, nonunion



© The Author(s) 2020. **Open Access** This article is licensed under a Creative Commons Attribution 4.0 International License (<https://creativecommons.org/licenses/by/4.0/>), which permits unrestricted use, sharing, adaptation, distribution and reproduction in any medium or format, for any purpose, even commercially, as long as you give appropriate credit to the original author(s) and the source, provide a link to the Creative Commons license, and indicate if changes were made.



INTRODUCTION

The first successful finger replantation was performed by Tamai, and major advances in replantation surgery have been made since then^[1]. Today, the survival of the replanted finger is no longer a sufficient criterion for success; rather, functional recovery is considered crucial.

Distal replantations, and especially those distal to the distal interphalangeal joint, are technically difficult, but many are likely to be functionally successful^[2]. Adequate vascular repair affects replant viability in the short term, but functional success is largely affected by bone fixation. The rate of the union in distal phalanx bone fractures is quite high; however, nonunion sometimes occurs due to inadequate fixation, segmental bone loss, soft tissue problems, and infection^[3]. Patients with nonunion often experience instability, pain, and radiological abnormalities. In those cases, a bone graft may be required.

Although not very popular, the olecranon bone graft is a useful option for this type of an operation due to the minimal donor morbidity and its ease of use in small bone defect reconstruction and nonunion therapy. To our best knowledge, few studies have evaluated the use of the olecranon bone graft as a treatment for nonunion after distal finger replantation. Our aim in this report was to present our experience of using olecranon grafts in our nonunion patients undergoing distal replantations.

METHODS

This study included a total of 14 (13 male and 1 female) patients who developed nonunion or segmental bone loss after replantation surgery between 2013 and 2019. Finger amputations of these patients were distal to the distal interphalangeal joint. Four amputations were at the Tamai zone 2 level and ten amputations were at the Tamai zone 1 level. The mean age was 34.5 years (range 19-54). Two patients had multiple finger amputations. Seven patients had crush amputations and seven patients had avulsion amputations. Two patients had segmental bone loss secondary to injury during the first surgery, and these defects were not reconstructed in the first operation to avoid vascular problems. In the other 12 patients, nonunion was diagnosed at the end of the fourth month based on radiological and clinical findings.

During the initial treatment, K-wires were used for all amputated fingers. Infection occurred in 3 patients, partial necrosis of the nail plate in 6 patients, segmental bone loss in 2 patients before initial surgery, and possibly inappropriate fixation in 3 patients that caused nonunions. The initial injuries were located at the arthrodesis site in 1 patient, at the tuft in three patients, and at the shaft of the distal phalanx in 10 patients.

All patients showed radiological and clinical findings (deformity, pain, and discomfort) before cancellous bone grafting. The overall mean time delay before the secondary treatment was 3.9 months (range 1-5 months).

Surgical technique

All surgeries were performed by two senior surgeons under axillary regional anesthesia. A 3 cm incision for bone graft harvesting was made starting 1-1.5 cm distal to the tip of the olecranon [Figure 1]. The periosteum was incised and elevated off the donor site of the olecranon. A cortical fenestra was elevated and preserved to expose the medullary space. The cancellous bone graft was harvested with an osteotome. The cortical piece was replaced and closed after harvesting the graft to prevent irregularity at the donor site. Cancellous bone grafts were used in all patients. The periosteum was repaired with absorbable sutures, with the skin sutured individually. Postoperatively, no splint was used for elbow immobilization.

The recipient site was reached through a unilateral incision made either lateral to the nail plate or through the nail plate, depending on the nail plate situation. The fibrous tissue was removed at the nonunion line

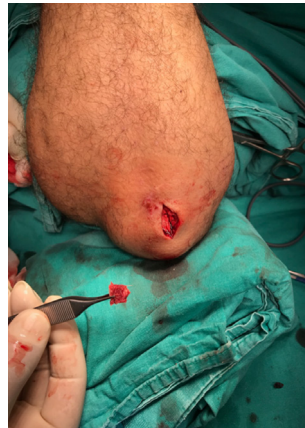

Figure 1. A 3 cm incision for bone graft harvesting was made starting 1-1.5 cm distal to the tip of the olecranon

Table 1. Location of nonunion and complications with the management of them

Patient No	Non-union area	Complication	Note
1	Thumb distal phalanx	Hematoma	Resolved after drainage
2	Index distal phalanx	None	-
3	Ring Finger distal phalanx	None	-
4	Index distal phalanx	Nail bed necrosis	Local flap
5	Long Finger distal phalanx	None	-
6	Little finger distal phalanx	None	-
7	Ring Finger distal phalanx	None	-
8	Little finger distal phalanx	None	-
9	Thumb distal phalanx	None	-
10	Long Finger distal phalanx	None	-
11	Ring Finger distal phalanx	None	-
12	Long Finger distal phalanx	None	-
13	Thumb distal phalanx	None	-
14	Little finger distal phalanx	None	-

until the healthy bone was excised. The bone graft was placed and fixed with one or two K-wires. The size of the bone grafts ranged from 20 mm × 6 mm × 6 mm to 3 mm × 3 mm × 4 mm.

Patients were discharged from the hospital on the same day as the operation. They were all given parenteral antibiotics during the hospital stay and continued to take oral antibiotics for 5 days after the operation. The operated finger was splinted for 6 weeks. The K-wires were removed at the end of the sixth week. The patients were assessed for pain, deformity, and instability after removal of the K-wires and during the post-operative visits. All patients had a final X-ray taken at least 6 months after bone grafting.

RESULTS

The mean follow-up period was 37 months (range 8-72 months). No major complications were seen in the donor region of the olecranon. One patient developed a hematoma in the donor area, but this issue was resolved after drainage. No fracture, palpable irregularity, discomfort, or pain was detected in the donor area in any of the patients.

One patient developed necrosis of the nail bed and the graft was exposed. The defect was covered with a local flap and no complications were seen after this revision. No viability problems were experienced in any replant after bone reconstruction. The radiological union was detected in all 14 patients at 6 months postoperatively [Table 1]. No pain, deformity, or instability was detected in the fingertip in any patient. We haven't seen any hypertrophic scars in the donor area.

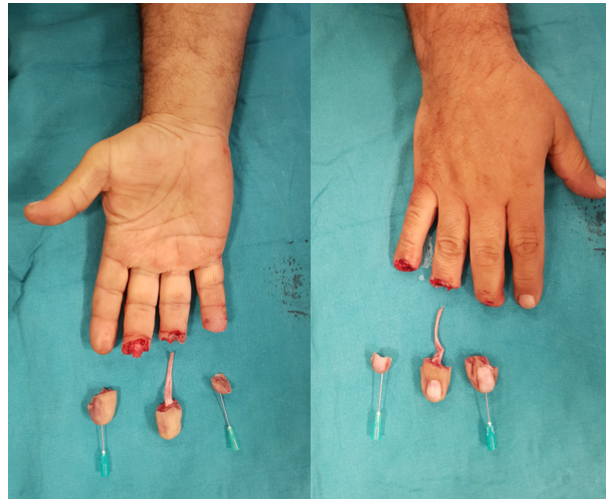


Figure 2. The patient had three fingers amputation due to an industrial accident

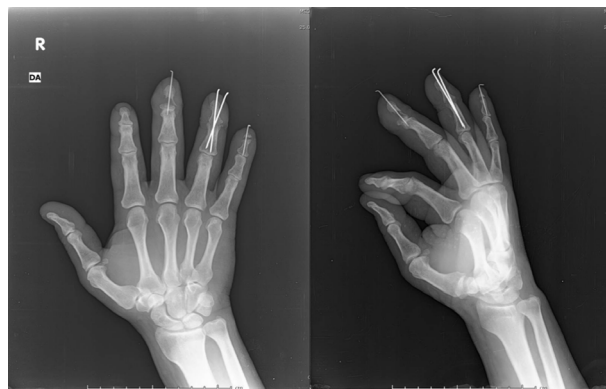

Figure 3. Segmental bone defect can be seen in the distal phalanx of the third finger

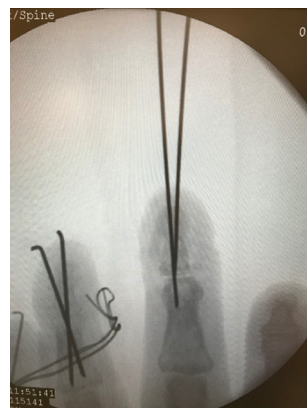

Figure 4. At 7 weeks after the first operation, an arthrodesis with an olecranon graft was performed on the 3rd distal interphalangeal joint

Case 1

A 45-year-old male patient underwent operations for 3 finger amputations [Figure 2]. The initial surgery, performed as a 3 finger replantation, was successful. Segmental bone loss was evident in the amputated 3rd finger, and the union line was probably distracted during fixation with the K-wire. These features resulted

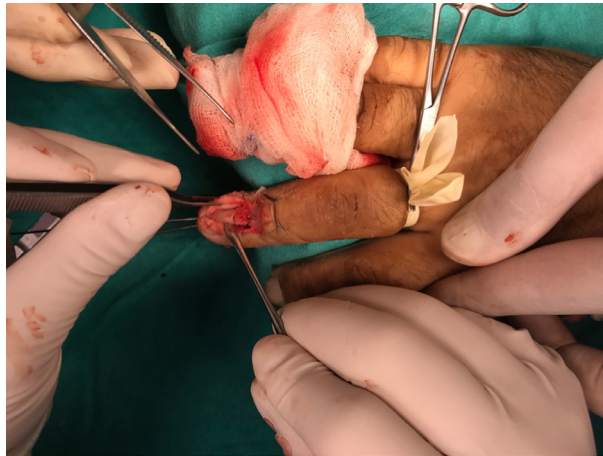


Figure 5. For this case, the thickness and stability of the nail bed was suitable, so grafting was performed through the incision in the middle of the nail bed

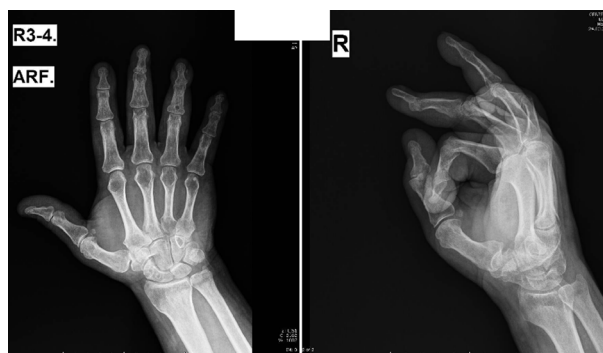

Figure 6. Six months after the olecranon bone grafting, the bony healing was complete

in nonunion in the 3rd finger, as confirmed by x-rays taken in the 6th week [Figure 3]. At 7 weeks after the first operation, an arthrodesis with an olecranon graft was performed on the 3rd distal interphalangeal joint [Figure 4]. The thickness and stability of the nail bed were suitable, so grafting was performed through the incision in the middle of the nail bed [Figure 5]. Six months after the olecranon bone grafting, the bony healing was complete [Figure 6].

DISCUSSION

Prehensile ability is essential for hand functions and requires a sensible and stable fingertip grip^[4]. Whenever it is technically possible, distal fingertip replantation is the gold standard method for replacing a missing fingertip^[2]. Replantation gives the best result, both cosmetically and functionally, in fingertip amputations, but the functional outcome depends on sensory recovery and stability. A nonunion impairs the stability of the fingertip^[5].

Bone fixation methods used for replantation should be simple, rapid, and consistent, so they should cause minimal injury to bone and soft tissue^[5]. The reported nonunion rate after replantation is between 3% and 19% in different studies^[1,6-8]. Autologous bone grafts harvested from the iliac crest are commonly used in reconstructive surgery. The bone promotes bone healing in fractures and provides structural support for reconstructive surgery^[9]. Iliac bone grafting can be performed under general anesthesia, but major complications include abdominal hernia, vascular injuries, deep infections at the donor site, neurologic injuries, hematoma, and iliac bone fractures. Harvesting of an iliac crest bone graft can, therefore, be associated with significant morbidity^[10].

Another option for cancellous bone grafting is the distal radius cancellous graft^[9]. This graft type has the important advantage that it can be performed under an axillary block and in the same surgical field. The complication rates for harvesting bone grafts over the distal radius are as low as 1.7%^[9], but they can include fracture at the donor site, local infection, DeQuervain's tenosynovitis, and neuroma of the superficial radial nerve^[11]. Patel *et al.*^[11] reported an overall complication rate, including bone graft failure, of 4%, as 38 patients (2.3%) required re-grafting with iliac bone, 21 patients (1.3%) developed DeQuervain's tenosynovitis, and 2 patients (0.1%) developed superficial radial nerve neuromas.

Although not very popular in previous studies, the olecranon graft is used as the first choice by the authors for the treatment of a distal phalanx nonunion. This graft has the important advantage that it can be performed under an axillary block and in the same surgical field. The graft can be used as a bone chip in amorphous, irregular, and small defects or it can be used as a structural cancellous graft in longitudinal defects. Harvesting takes about 10 min by the author. In addition to the short duration of the surgery, its other advantage is that the graft can be easily shaped with a scalpel. The donor site is also distant from important neurovascular structures, so the dissection can be done quite easily. The site can also be harvested with a trephine, which provides a further advantage of minimal scarring^[12].

A major disadvantage of the olecranon graft is that a sufficient graft may not be obtained for large defects. This graft is also not recommended for use in elderly or osteoporotic patients^[9]. Ozçelik *et al.*^[3] reported the successful use of cancellous olecranon grafts for treating nonunion of distal phalangeal fractures in 11 cases.

The timing of the bone grafting is also important. Jupiter *et al.*^[13] recommended waiting 4 months after the initial surgery, based on clinical and radiological findings. We haven't experienced any spontaneous union after 4 months too. Therefore, we had 12 of our patients wait 4 months for the surgical intervention for their nonunions. In two patients, the defect present at the replantation stage was evaluated as a segmental defect. Therefore, after vascular stabilization, grafting was performed without waiting for 4 months.

When using this technique, we preferred a mid-lateral approach to the distal phalanx as it does not disturb the vascular circulation. Ozçelik *et al.*^[3] preferred a mid-lateral incision for the 11 patients in their study. In cases where the nail bed is stable and thick, grafting can also be done through the nail bed. However, although this approach is more advantageous in terms of exposure, the graft may become exposed after dehiscence of the nail bed. Itoh *et al.*^[4] preferred grafting with a mid-palmar incision, which is advantageous in terms of exposure but has a theoretically higher risk of vascular injury and the possibility of painful scarring. With the mid-palmar technique, which Itoh *et al.*^[4] applied in 6 patients, no patient had any vascular or sensory problems.

In conclusion, we found that olecranon bone grafting is a safe and convenient method for the treatment of nonunion after distal finger replantation. It can be a preferred first choice for the treatment of nonunions of distal finger replantations.

DECLARATIONS

Authors' contributions

Corresponding, writing: Ercin BS
Data search: Ercin BS, Keles MK
Editing discussion part: Kabakas F
Editing: Ozcelik IB
Review: Mersa B

Availability of data and materials

The data that support the findings of this study are available on request from the corresponding author, (initials). The data are not publicly available due to (restrictions e.g. their containing information that could compromise the privacy of research participants).

Financial support and sponsorship

None.

Conflicts of interest

All authors declared that there are no conflicts of interest.

Ethical approval and consent to participate

All ethical approvals and informed consents were obtained according to Helsinki Declaration.

Consent for publication

Authors provide consent to publish before publication of the work.

Copyright

© The Author(s) 2020.

REFERENCES

1. Tamai S. Twenty years' experience of limb replantation--review of 293 upper extremity replants. *J Hand Surg Am* 1982;7:549-56.
2. Venkatramani H, Sabapathy SR. Fingertip replantation: technical considerations and outcome analysis of 24 consecutive fingertip replantations. *Indian J Plast Surg* 2011;44:237-45.
3. Özçelik IB, Kabakas F, Mersa B, Purisa H, Sezer I, et al. Treatment of nonunions of the distal phalanx with olecranon bone graft. *J Hand Surg Eur Vol* 2009;34:638-42.
4. Itoh Y, Uchinishi K, Oka Y. Treatment of pseudoarthrosis of the distal phalanx with the palmar midline approach. *J Hand Surg Am* 1983;8:80-4.
5. Lee SW, Lee DC, Kim JS, Roh SY, Lee KJ. Analysis of bone fixation methods in digital replantation. *Arch Plast Surg* 2017;44:53-8.
6. Nunley JA, Goldner RD, Urbaniak JR. Skeletal fixation in digital replantation. Use of the "H" plate. *Clin Orthop Relat Res* 1987;66-71.
7. Hoffmann R, Buck-Gramcko D. Osteosynthesis in digital replantation surgery. *Ann Chir Gynaecol* 1982;71:14-8.
8. Whitney TM, Lineaweaver WC, Buncke HJ, Nugent K. Clinical results of bony fixation methods in digital replantation. *J Hand Surg Am* 1990;15:328-34.
9. Mersa B, Özçelik IB, Kabakas F, Sacak B, Aydın A. Olecranon bone graft: revisited. *Tech Hand Up Extrem Surg* 2010;14:196-9.
10. Arrington ED, Smith WJ, Chambers HG, Bucknell AL, Davino NA. Complications of iliac crest bone graft harvesting. *Clin Orthop Relat Res* 1996;300-9.
11. Patel JC, Watson K, Joseph E, Garcia J, Wollstein R. Long-term complications of distal radius bone grafts. *J Hand Surg Am* 2003;28:784-8.
12. Özçelik B, Mersa B, Yesiloglu N. An easy way of harvesting olecranon bone graft in adults by using bone biopsy trephine. *J Hand Surg Am* 2013;38:622-3.
13. Jupiter JB, Koniuch MP, Smith RJ. The management of delayed union and nonunion of the metacarpals and phalanges. *J Hand Surg Am* 1985;10:457-66.